

HOSTED BY



ELSEVIER

Contents lists available at ScienceDirect

## Asian Pacific Journal of Tropical Biomedicine

journal homepage: [www.elsevier.com/locate/apjtb](http://www.elsevier.com/locate/apjtb)Review article <http://dx.doi.org/10.1016/j.apjtb.2016.09.003>

## Human and animal sarcocystosis in Malaysia: A review



Baha Latif, Azdayanti Muslim\*

Parasitology Discipline, Faculty of Medicine, Universiti Teknologi MARA, Sungai Buloh, Selangor, Malaysia

## ARTICLE INFO

## Article history:

Received 12 Apr 2016

Received in revised form 1 Aug, 2nd

revised form 12 Aug 2016

Accepted 25 Aug 2016

Available online 24 Sep 2016

## Keywords:

Sarcocystosis

Zoonosis

Human

Animal

Malaysia

## ABSTRACT

Sarcocystosis is a zoonotic disease caused by a coccidian intracellular protozoan parasite of the genus *Sarcocystis*. More than 200 *Sarcocystis* species have been recorded and the parasites are found in mammals, birds and reptiles. They require two hosts to complete their life cycle. In Malaysia, sarcocystosis was reported as a potential emerging food and water-borne disease after a series of large outbreak of human infections. There was not enough attention given before even though it was reported in both humans and animals. The first human case of invasive muscular sarcocystosis among local Malaysian was reported in 1975. Besides, a retrospective autopsy examination on 100 tongues revealed 21% positive cases. On top of that, a sero-epidemiological survey conducted in 243 subjects in West Malaysia showed that 19.7% had *Sarcocystis* antibodies. The clinical symptoms of muscular sarcocystosis were first described comprehensively in 1999. Meanwhile, many types of animals including livestock were found harbor the sarcocysts in their tissue. The first case of human intestinal sarcocystosis was reported in 2014. This review indicates that human sarcocystosis is currently endemic in Malaysia and parallel to that reported in animals. However, more studies and investigations need to be conducted since the source of human infection remains unknown.

## 1. Introduction

Sarcocystosis is a zoonotic disease caused by a coccidian intracellular protozoan of the genus *Sarcocystis*. *Sarcocystis* spp. requires two hosts to complete its life cycle; with sexual reproduction in the intestine of carnivores or omnivores (definitive host) and asexual reproduction in the tissues of herbivores (intermediate hosts) [1]. It was first observed in 1843 by Miescher as white threadlike cysts and simply known as Miescher's tubule for 20 years [1]. To date, there are more than 200 *Sarcocystis* species recorded in the world and the parasites can be found in the tissues of mammals, humans, birds, reptiles and probably in fish [1,2].

There are two forms of sarcocystosis inflicting in man; intestinal and muscular. Intestinal sarcocystosis is acquired when

humans eat raw or undercooked meat which harbors the cystic stage of the parasite. Man becomes the definitive host after the ingestion of raw beef or pork infected with *Sarcocystis hominis* (*S. hominis*) and *Sarcocystis suihominis* (*S. suihominis*), respectively [2]. If acquired, it can cause gastroenteritis. However, in most people, the infections are asymptomatic and self-limiting [1,2]. Muscular sarcocystosis infection is acquired by the ingestion of contaminated food and water with sporocysts [3]. In this case, the parasite forms the muscular type in which consequently cause clinical signs such as fever, myalgia and arthralgia. Generally, based on early reports, the prevalence of human extra intestinal sarcocystosis was considered low with only less than 100 cases reported worldwide [1].

In Malaysia, muscular sarcocystosis was reported as a potential emerging food-borne zoonosis after a series of large outbreak of human infections. However, there was not enough attention given before even though it was reported in both humans and animals. Therefore, the aim of this review is to provide the latest updates regarding sarcocystosis in humans and animals in Malaysia.

## 2. Human muscular sarcocystosis

Historically, the first case of muscular sarcocystosis in Malaysia recorded involving an English man who had returned

\*Corresponding author: Azdayanti Muslim, Faculty of Medicine, University Teknologi MARA, Sungai Buloh Campus, Jalan Hospital, 47000, Sungai Buloh, Selangor, Malaysia.

Tel: +60 125740014, +60 36126 7428

Fax: +60 36126 7073

E-mail: [azdayanti@salam.uitm.edu.my](mailto:azdayanti@salam.uitm.edu.my)

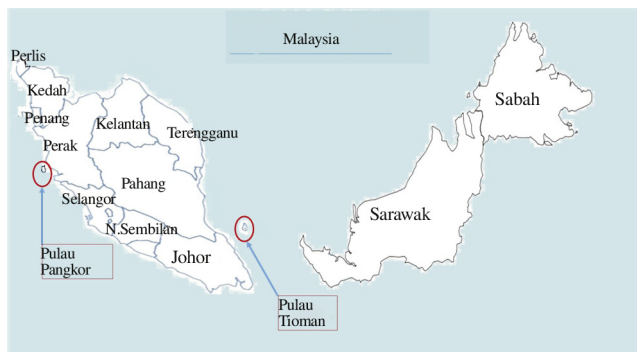Foundation Project: Partly supported by Ministry of Education, Malaysia under Research Acculturation Grant Scheme (RAGS) Grant (600-RMI/RAGS 5/3 (76/2014)).

Peer review under responsibility of Hainan Medical University. The journal implements double-blind peer review practiced by specially invited international editorial board members.

to England from Sarawak, East Malaysia [4]. Second case was reported by Jeffrey in 1974, in patient who also had returned to U.K from Malaysia [5]. However, the first human case of extra-intestinal sarcocystosis among local Malaysian was reported in 1975 which involved a Malay man [6] followed by an incidental finding of sarcocyst in nasopharyngeal/oropharyngeal tissues of an Orang Asli girl with malignancy [7] within the same year. Since that, a total of ~13 cases of invasive muscular sarcocystosis have been reported sporadically until 1992 [8–10]. However, most of the findings were incidentally taken from autopsied/biopsied specimens with no symptoms described. In addition, most of the cases were associated with malignancies. Nevertheless, seroprevalence study conducted in 1978 showed that 20% out of 243 respondents from four main ethnic groups in Malaysia had antibodies for *Sarcocystis*, indicating the endemicity of the disease [11]. On top of that, examination of human tongue tissue in 100 routine autopsies revealed a prevalence rate of 21% [12].

The clinical symptoms of the infection were first described in Malaysia after the first outbreak reported in 1999 involving 7 out of 15 US servicemen [13]. Acute manifestations including fever, myalgia and bronchospasm were noted and extensive investigation showed transient lymphadenopathy and subcutaneous nodules associated with eosinophilia, raised erythrocyte sedimentation rate, and elevated levels of muscle creatinine kinase. Muscle biopsy examination from one patient revealed microscopic sarcocysts. No more case of human sarcocystosis has been reported since 1999 until two large outbreaks of probable acute symptomatic muscular sarcocystosis which happened recently among travelers in two Malaysian islands (Figure 1), Tioman Island is located 32 km off the East Coast of Peninsular Malaysia, while Pangkor Island is located in Perak, 3.5 km off the West Coast of Peninsular Malaysia.

The outbreak were known to start during the late summer of July–August 2011 after Geo Sentinel (The surveillance program of the International Society of Travel Medicine and Centers for Disease Control) reported at least 32 acute cases of extra-intestinal sarcocystosis suspected among travelers upon returning home from Tioman Island [14]. Most of them were from Germany while the others were from Europe, North America and Asia. The clinical symptoms of fever and severe muscle pain were recorded within days and weeks in addition to the laboratory findings which had shown peripheral eosinophilia and the rise of serum creatinine phosphokinase level. Further results from muscle biopsy taken from two patients had revealed the possibility of sarcocystosis in the patients [15,16].



**Figure 1.** Location of the reported cases of human muscular sarcocystosis in Malaysia.

Following that, a survey for sarcocystosis was conducted soon after the outbreak in Tioman Island by Malaysian authorities but no trace of *Sarcocystis* parasites were found in humans, animals or in the water samples during that time [14]. A small number of samples was the limitation of the study. Moreover, no wild life was included for the screening of the study.

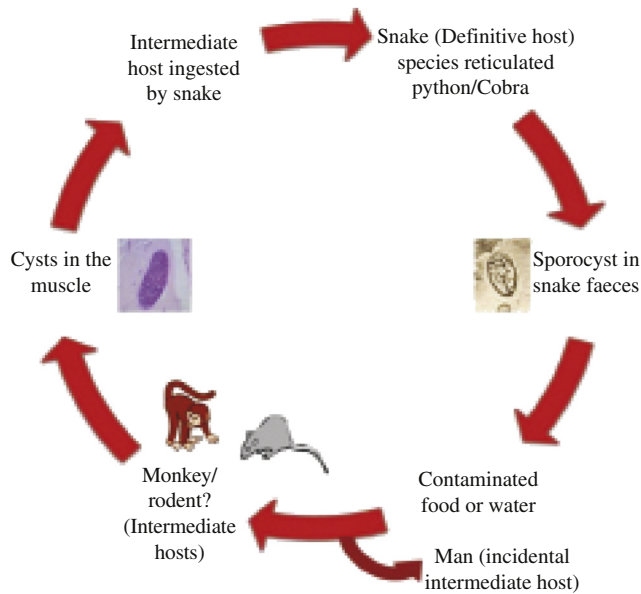
Approximately few months to one year later (July–August 2012), another wave of outbreak involving 65 people from various nationalities and with the history of travelling to Tioman Island were identified [17] with having almost similar symptoms as reported before. This second group of patients formed a total of 100 cases suspected with muscular sarcocystosis. Muscle biopsy taken from eight patients revealed that six of them had myositis and intramuscular cysts were identified in two patients [17]. Slesak and his colleagues in their further investigations involving 26 patients in German reported that the incubation period was approximately 2 weeks with biphasic development [18]. The third wave of extra intestinal sarcocystosis-like illness was suspected in May 2014 comprising 6 German patients [19]. All patients suffered from fever, myalgia and headache. No muscle biopsies were taken. However, the history, clinical symptoms and laboratory findings had shown the possibility of sarcocystosis.

Another concurrent outbreak of symptomatic sarcocystosis was reported within the same time frame (January 2012) but from different vicinity. From 92 college students and teachers, 89 of them were identified with symptoms including fever, myalgia, headache and cough after visiting Pangkor Island [20]. Molecular detection from biopsied specimens of 4 patients had revealed that the infection was caused by *Sarcocystis nesbitti* (*S. nesbitti*) [20–22]. Non-Malaysians were noticed to experience the symptoms longer and severe than the Malaysians [21]. Phylogenetic analysis suggested the source of infection was probably from snakes [22], but until now, the findings are still uncertain.

Therefore, following the latest outbreaks, it is now postulated that the possible source of infection of human muscular sarcocystosis in Malaysia is the contamination of food and water with sporocysts of *S. nesbitti* excreted with snakes (definitive hosts). Historically, the species was first discovered in the skeletal muscle of a rhesus monkey in China [23]. Through intensive research conducted in Malaysia in search for the clue and source of infection, *S. nesbitti* have been identified in the fecal sample of *Naja khaoutia* (cobra) and in reticulated python by molecular analysis [24]. The latter findings suggested the possibility of snake as the source of infection with rhesus monkey or rats probably serve as intermediate host (Figure 2). The summary of human muscular sarcocystosis in Malaysia is shown in Table 1.

The spectrum of clinical symptoms is broad and varies among individual ranging from asymptomatic to chronic and prolonged form of infection in which can also cause relapse [32]. Myalgia with or without fever, > 5% eosinophilia, elevated serum creatinine phosphokinase levels, myositis and negative trichinellosis and toxoplasmosis by serology are considered as the most important parameters for acute muscular sarcocystosis [32]. It was noted that the elevated level of blood eosinophils and serum creatinine phosphokinase were prominent during the late phase (~4 weeks post-departure) of period [19,32].

Generally, there is no definite treatment for human muscular sarcocystosis. The infection is usually mild and self-limiting in



**Figure 2.** Possible sources of infection with human muscular sarcocystosis in Malaysia.

most of the cases, and no treatment is required. Anti-parasitic agents such as albendazole or ivermectin are used to suppress the symptoms of the infection. Oral steroids such as prednisolone (used for severe myalgia to reduce inflammation associated with muscular involvement) have been used for treatment in some of the cases [19,32]. Metronidazole and cotrimoxazole (antibacterial) are used for eosinophilic myositis. Recent investigation following the outbreak cases of muscular sarcocystosis in Tioman Island indicated the effectiveness of cotrimoxazole in prolonged symptoms of the disease [31].

**3. Animal muscular sarcocystosis**

*Sarcocystis* species requires alternate intermediate host (prey) – definitive host (predator) relationship to complete the life cycle. In Malaysia, sarcocysts have been found in the muscle tissue of a variety of wild animals (intermediate hosts) including slow loris [33], long tailed monkey [34], and rodents [35,36]. Apart from that, muscular sarcocystosis was reported in mammals and birds with 15% and 20% infection rate respectively in a study

**Table 1**  
Reported cases of human muscular sarcocystosis in Malaysia during 1965–2014.

Country of patients	No. of cases	Location	Summary	Biopsy/Autopsy findings (sarcocyst)	Species	Reference
United Kingdom	1	EM	A biopsy (leg) for weakness of the arms and legs, high eosinophilia	+	–	[4]
United Kingdom	1	PM	A biopsy (pectoral) for muscle swelling and high eosinophilia	+	–	[5]
Malaysia	1	PM	Malay man with hoarseness of voice. Incidental finding at biopsy (laryngeal)	+	–	[6]
Malaysia	1	PM	Orang Asli girl with malignancy. Incidental finding at autopsy (oropharyngeal)	+	–	[7]
Malaysia	1	PM	Incidental finding at biopsy (flexor muscle)	+	–	[9]
Malaysia	1	PM	Incidental finding at autopsy revealed immature cyst	+	–	[8]
Malaysia	3	PM	Incidental finding at biopsy (vastus lateralis, deltoid, biceps muscle)	+	–	[25]
Malaysia	1	PM	Incidental finding at biopsy (tongue muscle)	+	Resembling <i>Sarcocystis booliati</i>	[26]
Malaysia	2	EM	Incidental findings following biopsy (nasopharynx) associated with malignancy.	+	–	[27]
Malaysia	1	PM	Incidental findings following biopsy	+	–	[28]
	3	PM	Incidental findings following biopsy	+	–	[29]
	21	PM	Study on routine autopsy specimens (tongue muscles)	+ in 21 samples	–	[12]
	2	PM	Two women with neoplastic conditions. Incidental finding at biopsy.	+	–	[30]
United State	7	PM	Outbreak among American soldiers. Fever, myalgia, bronchospasm, rash, subcutaneous nodules, eosinophilia, high erythrocyte sedimentation rate, high creatinine kinase.	+ in 1 patient	–	[13]

(continued on next page)

**Table 1** (continued)

Country of patients	No. of cases	Location	Summary	Biopsy/Autopsy findings (sarcocyst)	Species	Reference
Germany, France, EU countries, Canada, Singapore	~100	Tioman Island	First and second outbreak (2011–2012) among travellers. Fever, myalgia, arthralgia, asthenia, headache, cough, diarrhea, pruritic rash, edema,	+ in 6 patient	<i>S. nesbitti</i> (PCR)	[14,15,17,18,31]
Malaysia, China, Nepal, Korea, Indonesia, Others	89	Pangkor Island	Outbreak (2012) among both Malaysian and non-Malaysians. Fever, myalgia, facial swelling, cough, headache.	+ in 3 patients	<i>S. nesbitti</i> (PCR)	[20–22]
Germany	6	Tioman Island	Suspected third wave of outbreak (2014) among travellers. Fever, headache, myalgia, arthralgia, neck pain.	Not done	Not identified	[19]

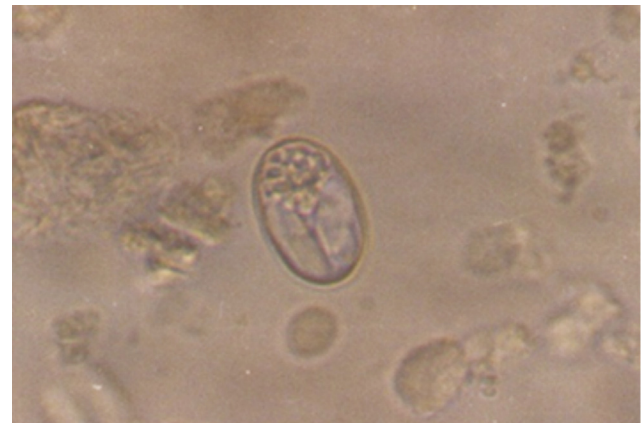EM: East Malaysia; PM: Peninsular Malaysia; +: Sarcocystosis/cysts are seen microscopically; -: The exact species was not mentioned nor identified.

conducted among necropsied wild captive and zoo animals [37]. Meanwhile, in livestock (Table 2), sarcocysts have been identified in water buffaloes [38–41], sheep [42,43], goats [43,44] and cattles [41,43,45].

The infection is usually mild and animals with muscular sarcocystosis seldom show any symptoms. However, some species are known to cause pathological effects in meat-producing animals including anorexia, anemia, weight loss, muscle weakness, lymphadenopathy, abortion, and eventually death in severe infections [2]. The severity might be influenced by species of the *Sarcocystis* parasite, intensity of the infection and the condition of the animal (during pregnancy or lactation, stress) [2]. *Sarcocystis cruzi* (*S. cruzi*) in cattle is the most prevalent and pathogenic [46]. However, the parasites are usually seen mainly as an incidental finding at necropsy.

Even though many reports have been established in Malaysia, the information regarding the source of infections (the definitive hosts) are relatively undetermined. The intermediate host/prey becomes infected by ingesting contaminated food/water or environment with the sporocysts shed in the feces of the definitive hosts (Figure 3) [2]. Cats and dogs are known as the definitive hosts for *Sarcocystis fusiformis* (*S. fusiformis*) and *Sarcocystis levinei*, respectively [38,40]. Complete life cycle also was documented for *Sarcocystis orientalis/Sarcocystis singaporensis*, *Sarcocystis villivillosus* and *Sarcocystis zamani*

in rats (*Rattus norvegicus*), which a Malaysian snake python served as the definitive host [47].



**Figure 3.** Sporocyst in dog's fecal sample (100×).

In sheep, four species of *Sarcocystis* have been documented. *S. ovicanis* and *Sarcocystis arieticanis* are pathogenic, form microscopic cysts, and are transmissible by dogs while *Sarcocystis ovifelis* and *Sarcocystis medusiformis* are non-pathogenic, form macroscopic cysts, and transmissible by cats. In goats, there are two microscopic forms: *Sarcocystis capracanis* and

**Table 2**

Muscular sarcocystosis among meat producing animals in Malaysia.

Type of animal	Number of samples	Type	No. of positive [n (%)]*	<i>Sarcocystis</i> sp.	Definitive host	Reference
Water buffaloes	Not recorded	Macroscopic	0 (0.0)	<i>S. fusiformis</i>	Cats	[40]
Water buffaloes	Not recorded	Microscopic	0 (0.0)	<i>Sarcocystis levinei</i>	Dogs	[38,39]
Sheep	72	Microscopic	38 (52.8)	Unknown	–	[42]
Water buffaloes	18	Microscopic	12 (66.7)	Unknown	–	[41]
Cattle	102	Microscopic	37 (36.2)	<i>S. cruzi</i>	Dogs	[41]
Sheep	43	Microscopic	37 (86.0)	<i>S. ovicanis</i>	Dogs	[43]
Goats	89	Microscopic	55 (61.8)	<i>S. capracanis</i>	Dogs	[43]
Cattle	77	Microscopic	22 (28.6)	<i>S. bovicanis</i>	Dogs	[43]
Goat	105	Microscopic	55 (52.4)	<i>S. capracanis</i>	Dogs	[44]
Cattle	11	Microscopic	11 (100.0)	<i>S. cruzi</i>	Dogs	[45]

\*: The positive rate was based on microscopic examination result; *Sarcocystis ovicanis*: *S. ovicanis*; *Sarcocystis bovicanis*: *S. bovicanis*; *S. capracanis*: *S. capracanis*; -: The exact species was not mentioned nor identified.



*Sarcocystis hircicanis*, which dogs served as the definitive hosts. In cattle, the transmission of *S. bovicanis* is via canids, *Sarcocystis hirsute* is via felids and *S. hominis* is via human [4]. PCR studies in Malaysia have identified *S. ovicanis*, *S. capracanis*, and *S. bovicanis* for sheep, goats and cattles, respectively [43]. Species identification either by molecular detection or ultrastructural studies is crucial because some species are more pathogenic to the livestock and most importantly, to detect the zoonotic species such as *S. hominis*.

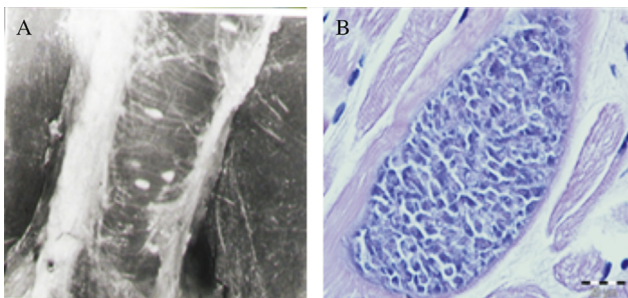
#### 4. Human and animal intestinal sarcocystosis

Human serves both as the definitive and intermediate hosts in the parasite's life cycle. The known species where man is confirmed as a definitive host are *S. hominis* and *S. suihominis* which can be acquired from infected beef and pork, respectively [2].

Only one case of intestinal sarcocystosis has been reported in Malaysia involving an asymptomatic female Orang Asli from Temiar group [48]. However, the exact species was not determined in latter study as diagnosis was only performed by microscopic examination. It is speculated that the prevalence of intestinal sarcocystosis is underreported due to a lack of study conducted in Malaysia and the symptoms are usually mild or self-limiting. Most of the symptomatic cases found in natural-acquired or experimental study in other countries reported that the infected patients or volunteers experienced nausea, vomiting, acute or chronic diarrhea and abdominal pain [1]. The range of the clinical manifestations depends on the intensity of infection or the species of the *Sarcocystis* parasites. Sarcocysts from pork is believed to cause more serious problem than beef [2].

#### 5. Diagnosis

The diagnosis of muscular sarcocystosis is usually made by detection of macroscopic or microscopic cysts (Figure 4) in the tissue sample of skeletal muscle, tongue, esophagus, diaphragm and heart. Macroscopic cyst can be seen by naked eyes, but it is restricted to a few species such as *S. fusiformis* in water buffalo and *S. nesbitti* in long tailed monkey [49]. The cysts are spindle to oval in shape, two stages are recognized, the peripheral metrocytes and large numbers of centrally located banana-shaped bradyzoites. Sizes of cysts and bradyzoites vary among species. These differences in the size of the cysts and internal structures could attribute to the cyst age and strains of the *Sarcocystis* spp.




**Figure 4.** A: Macroscopic sarcocysts in animal muscle tissue; B: Microscopic sarcocyst in animal muscle tissue. H&E 100 $\times$ .

The actual prevalence of muscular sarcocystosis needs to be addressed carefully due to the difference in approached diagnostic. Direct muscle/tissue compression between two glass slides is considered as the most rapid and easiest method for microscopic examination. The technique has been used widely in Malaysia [37,41,43,44], but its sensitivity is low [44]. To improve the detection, Ng *et al.* has suggested the use of modified methylene blue staining (without acetic acid) in a tissue compression technique [50]. Moreover, the latter technique was reported to have a moderate agreement with nested PCR. Therefore, it would be useful in examining large numbers of samples.

Other methods used for microscopic examination are histological examination with H&E or Giemsa staining and peptic digestion and immunofluorescent [51]. In Malaysia, indirect fluorescence antibody technique method was used to detect the prevalence of antibodies to *Sarcocystis*, but some serum showed positive reactions to *Toxoplasma* as well [11]. Whether due to cross reaction or poly-parasitism, it could not be justified. For the identification of the species, most of the previous studies depended on the morphology, size of the cyst (Figure 5) and the thickness of the cyst wall. Electron microscopy was commonly used to differentiate the structure of the sarcocysts [34,38].

Lately, molecular-based techniques (PCR) have been used frequently especially for the identification of the species due to its reliability and accuracy. However, it should be incorporated with other standard detection methods for sarcocystosis [44]. The final diagnosis is still by looking at the presence of sarcocysts in the autopsied, biopsied or necropsied specimens. In Malaysia, *S. ovicanis*, *S. capracanis*, *S. bovicanis* and the latest *S. nesbitti*, *Sarcocystis singaporensis* and *Sarcocystis zuoi* have been identified by molecular techniques [20,22,43,45,47].

For intestinal sarcocystosis, diagnosis is usually made by the detection of oocyst/sporocyst in the stool sample of humans or animals (predators/definitive hosts). Generally, acid-fast stain such as Ziehl–Neelsen staining is used to demonstrate apicomplexan parasite including *Sarcocystis* species. However, the latter technique is limited to the time of sporocysts excretion. According to Dubey, the pre-patent periods for *S. hominis* and *S. suihominis* are 14–18 days and 11–13 days, respectively [2]. To the best of our knowledge, only



**Figure 5.** Different size of microsarcocysts from animal tissue.

one case of human intestinal sarcocystosis has been reported in Malaysia by microscopic examination but the species could not be determined [48]. While in animals, intestinal sarcocystosis infection is commonly detected by mucosal scrapings during the post mortem rather than stool examination.

Considering the limitations, molecular studies could be the best way to identify the *Sarcocystis* parasite. Latest finding by Lau *et al.* (2013) has identified *Sarcocystis* spp in the stool sample of snakes located in Malaysia by phylogenetic analyses based on 18S rRNA sequenced data [24]. Still, both microscopy and molecular analysis are important and should be incorporated together for future studies.

## 6. Conclusion

Extra precautions should be undertaken to avoid the infections. Following recent outbreaks, Centers for Disease Control has suggested few recommendations for safe food and water consumption. Any person who is experiencing fever or prominent myalgia with travelling history to Tioman Island/Pangkor Island or any tropical countries is encouraged to seek some medical checkup. Human is most likely to acquire the infections by accidental ingestion of sporocysts shed by some carnivorous or predatory animals which would have acquired the infection by ingesting sarcocysts found in the herbivorous intermediate host. Human sarcocystosis is endemic in Malaysia and parallels to that reported in animals. It is suggested that the possibility of snake as the source of infection with rhesus monkey or rats may serve as the intermediate host.

## Conflict of interest statement

We declare that we have no conflict of interest.

## Acknowledgments

We would like to thank our institution, University Teknologi MARA for continuous support in the form of providing the facilities for our laboratory works. This paper is part of the research work funded by Ministry of Education, Malaysia under Research Acculturation Grant Scheme Grant (600-RMI/RAGS 5/3 (76/2014)).

## References

- [1] Fayer R, Esposito DH, Dubey JP. Human infections with *Sarcocystis* species. *Clin Microbiol Rev* 2015; **28**(2): 295-311.
- [2] Dubey JP. Foodborne and waterborne zoonotic sarcocystosis. *Food Waterborne Parasitol* 2015; **1**(1): 2-11.
- [3] Dorny P, Praet N, Deckers N, Gabriel S. Emerging food-borne parasites. *Vet Parasitol* 2009; **163**(3): 196-206.
- [4] Mandour AM. Pathology and symptomatology of *Sarcocystis* infection in man. *Trans R Soc Trop Med Hyg* 1965; **59**(4): 432-5.
- [5] Jeffrey HC. Sarcosporidiosis in man. *Trans R Soc Trop Med Hyg* 1974; **68**(1): 17-29.
- [6] Kutty MK, Dissanaiké AS. A case of human *Sarcocystis* infection in West Malaysia. *Trans R Soc Trop Med Hyg* 1975; **69**(5-6): 503-4.
- [7] Kutty MK, Mohan Das A, Dissanaiké AS. *Sarcocystis* infection in an Orang Asli: the second human case from Malaysia. *Southeast Asian J Trop Med Public Health* 1975; **6**(3): 400-1.
- [8] Prathap K, Dissanaiké AS. The fourth case of *Sarcocystis* infection in man in Malaysia. *Southeast Asian J Trop Med Public Health* 1978; **9**(3): 452-3.
- [9] Prathap K, Dissanaiké AS. Third case of *Sarcocystis* from man in Malaysia. *Southeast Asian J Trop Med Public Health* 1976; **7**(3): 489.
- [10] Kan SP, Pathmanathan R. Review of sarcocystosis in Malaysia. *Southeast Asian J Trop Med Public Health* 1991; **22**(Suppl 22): 129-34.
- [11] Thomas V, Dissanaiké AS. Antibodies to *Sarcocystis* in Malaysians. *Trans R Soc Trop Med Hyg* 1978; **72**(3): 303-6.
- [12] Wong KT, Pathmanathan R. High prevalence of human skeletal muscle sarcocystosis in south-east Asia. *Trans R Soc Trop Med Hyg* 1992; **86**(6): 631-2.
- [13] Arness MK, Brown JD, Dubey JP, Neafie RC, Granstrom DE. An outbreak of acute eosinophilic myositis attributed to human *Sarcocystis* parasitism. *Am J Trop Med Hyg* 1999; **61**(4): 548-53.
- [14] Husna Maizura AM, Khebir V, Chong CK, Shah A, Hakim L. Surveillance for sarcocystosis in Tioman Island, Malaysia. *Malays J Public Health Med* 2012; **12**(2): 39-44.
- [15] Sonnenburg FV, Cramer JP, Freedman DO, Plier DA, Esposito DH, Sotir MJ, et al. Notes from the field: acute muscular sarcocystosis among returning travelers-Tioman Island, Malaysia, 2011. *MMWR Morb Mortal Wkly Rep* 2012; **61**(2): 37-8.
- [16] Tappe D, Ernestus K, Rauthe S, Schoen C, Frosch M, Muller A, et al. Initial patient cluster and first positive biopsy findings in an outbreak of acute muscular *Sarcocystis*-like infection in travelers returning from Tioman island, Peninsular Malaysia, in 2011. *J Clin Microbiol* 2013; **51**(2): 725-6.
- [17] Esposito DH, Freedman DO, Neumayr A, Parola P. Ongoing outbreak of an acute muscular *Sarcocystis*-like illness among travellers returning from Tioman Island, Malaysia, 2011–2012. *Euro Surveill* 2012; **17**(45): 20310.
- [18] Slesak G, Tappe D, Keller C, Cramer J, Güthoff W, Zanger P, et al. [Muscular sarcocystosis after travel to Malaysia: a case series from Germany]. *Dtsch Med Wochenschr* 2014; **139**(19): 990-5. German.
- [19] Tappe D, Stich A, Langeheinecke A, von Sonnenburg F, Muntau B, Schafer J, et al. Suspected new wave of muscular sarcocystosis in travellers returning from Tioman Island, Malaysia, May 2014. *Euro Surveill* 2014; **19**: 20816.
- [20] Abubakar S, Teoh BT, Sam SS, Chang LY, Johari J, Hooi PS, et al. Outbreak of human infection with *Sarcocystis nespitti*, Malaysia, 2012. *Emerg Infect Dis* 2013; **19**(12): 1989-91.
- [21] Italiano CM, Wong KT, AbuBakar S, Lau YL, Ramli N, Syed Omar SF, et al. *Sarcocystis nespitti* causes acute, relapsing febrile myositis with a high attack rate: description of a large outbreak of muscular sarcocystosis in Pangkor Island, Malaysia, 2012. *PLoS Negl Trop Dis* 2014; **8**(5): e2876.
- [22] Lau YL, Chang PY, Tan CT, Fong MY, Mahmud R, Wong KT. *Sarcocystis nespitti* infection in human skeletal muscle: possible transmission from snakes. *Am J Trop Med Hyg* 2014; **90**(2): 361-4.
- [23] Mandour AM. *Sarcocystis nespitti* n. sp. from the rhesus monkey. *J Protozool* 1969; **16**(2): 353-4.
- [24] Lau YL, Chang PY, Subramaniam V, Ng YH, Mahmud R, Ahmad AF, et al. Genetic assemblage of *Sarcocystis* spp. in Malaysian snakes. *Parasit Vectors* 2013; **6**: 257.
- [25] Tappe D, Abdullah S, Heo CC, Kannan Kutty M, Latif B. Review paper human and animal invasive muscular sarcocystosis in Malaysia—recent cases, review and hypotheses. *Trop Biomed* 2013; **30**(3): 355-66.
- [26] Pathmanathan R, Kan SP. Human *Sarcocystis* infection in Malaysia. *Southeast Asian J Trop Med Public Health* 1981; **12**: 247-50.
- [27] Pathmanathan R, Kan SP. Two cases of human sarcocystosis in East Malaysia. *Med J Malays* 1987; **42**(3): 212-4.
- [28] Pathmanathan R, Jayalakshmi P, Kan SP. A case of human muscular sarcocystosis in Malaysia. *J Malays Soc Health* 1988; **6**: 45-7.
- [29] Pathmanathan R, Kan SP. Three cases of human *Sarcocystis* infection with a review of human muscular sarcocystosis in Malaysia. *Trop Geogr Med* 1992; **44**(1-2): 102-8.

- [30] Shekhar KC, Pathmanathan R, Krishnan R. Human muscular sarcocystosis associated with neoplasms? Case report. *Trop Biomed* 1998; **15**(2): 61-4.
- [31] Slesak G, Schafer J, Langeheinecke A, Tappe D. Prolonged clinical course of muscular sarcocystosis and effectiveness of cotrimoxazole among travelers to Tioman Island, Malaysia, 2011–2014. *Clin Infect Dis* 2014; **60**(2): 329.
- [32] Esposito DH, Stich A, Epelboin L, Malvy D, Han PV, Bottieau E, et al. Acute muscular sarcocystosis: an international investigation among ill travelers returning from Tioman Island, Malaysia, 2011–2012. *Clin Infect Dis* 2014; **59**(10): 1401-10.
- [33] Zaman V. *Sarcocystis* sp. in the slow loris, *Nycticebus coucang*. *Trans R Soc Trop Med Hyg* 1970; **64**(1): 195-6.
- [34] Kan SP, Prathap K, Dissanaiké AS. Light and electron microstructure of a *Sarcocystis* sp. from the Malaysian long-tailed monkey, *Macaca fascicularis*. *Am J Trop Med Hyg* 1979; **28**(4): 634-42.
- [35] Kan SP. Ultrastructure of the cyst wall of *Sarcocystis* spp. from some rodents in Malaysia. *Int J Parasitol* 1979; **9**(5): 475-80.
- [36] Ambu S, Yeoh EYS, Mak JW, Chakravarthi S. Prevalence of *Sarcocystis* spp. in rodents in Peninsular Malaysia. *Int e-J Sci Med Edu* 2011; **5**(2): 29-38.
- [37] Latif B, Vellayan S, Omar E, Abdullah S, Mat Desa N. Sarcocystosis among wild captive and zoo animals in Malaysia. *Korean J Parasitol* 2010; **48**(3): 213-7.
- [38] Kan SP, Dissanaiké AS. Studies on *Sarcocystis* in Malaysia. II. Comparative ultrastructure of the cyst wall and zoites of *Sarcocystis levinei* and *Sarcocystis fusiformis* from the water buffalo, *Bubalus bubalis*. *Z Parasitenkd* 1978; **57**(2): 107-16.
- [39] Dissanaiké AS, Kan SP. Studies on *Sarcocystis* in Malaysia. I. *Sarcocystis levinei* n. sp. from the water buffalo *Bubalus bubalis*. *Z Parasitenkd* 1978; **55**(2): 127-38.
- [40] Dissanaiké AS, Kan SP, Retnasabapathy A, Baskaran G. Developmental stages of *Sarcocystis fusiformis* (Railliet, 1897) and *Sarcocystis* sp., of the water buffalo, in the small intestines of cats and dogs respectively. *Southeast Asian J Trop Med Public Health* 1977; **8**(3): 417.
- [41] Latif B, Vellayan S, Heo CC, Kannan Kutty M, Omar E, Abdullah S, et al. High prevalence of muscular sarcocystosis in cattle and water buffaloes from Selangor, Malaysia. *Trop Biomed* 2013; **30**(4): 699-705.
- [42] Norlida O, Zarina M, Latif B, Abo R, Al-Sultan I. A histopathological appraisal of ovine sarcocystosis in Kelantan. *J Adv Biomed Pathobiol Res* 2012; **2**(4): 137-42.
- [43] Latif B, Kannan Kutty M, Muslim A, Hussaini J, Omar E, Heo CC, et al. Light microscopy and molecular identification of *Sarcocystis* spp. in meat producing animals in Selangor, Malaysia. *Trop Biomed* 2015; **32**(3): 444-52.
- [44] Kutty MK, Latif B, Muslim A, Hussaini J, Daher AM, Heo CC, et al. Detection of sarcocystosis in goats in Malaysia by light microscopy, histology, and PCR. *Trop Anim Health Prod* 2015; **47**(4): 751-6.
- [45] Ng YH, Fong MY, Subramaniam V, Shahari S, Lau YL. Short communication: genetic variants of *Sarcocystis cruzi* in infected Malaysian cattle based on 18S rDNA. *Res Vet Sci* 2015; **103**: 201-4.
- [46] Lindsay DS, Blagburn BL, Braund KG. *Sarcocystis* spp. and sarcocystosis. *Br Med J* 1995; **5**(3): 249-54.
- [47] Beaver PC, Maleckar JR. *Sarcocystis singaporensis* Zaman and Colley, (1975) 1976. *Sarcocystis villivillosi* sp. n., and *Sarcocystis zamani* sp. n.: development, morphology, and persistence in the laboratory rat, *Rattus norvegicus*. *J Parasitol* 1981; **67**(2): 241-56.
- [48] Lee SC, Ngui R, Tan TK, Muhammad Aidil R, Lim YA. Neglected tropical diseases among two indigenous subtribes in Peninsular Malaysia: highlighting differences and co-infection of helminthiasis and sarcocystosis. *PLoS One* 2014; **9**(9): e107980.
- [49] Yang ZQ, Wei CG, Zen JS, Song JL, Zuo YX, He YS, et al. A taxonomic re-appraisal of *Sarcocystis nesbitti* (Protozoa: Sarcocystidae) from the monkey *Macaca fascicularis* in Yunnan, PR China. *Parasitol Int* 2005; **54**(1): 75-81.
- [50] Ng YH, Subramaniam V, Lau YL. Modified use of methylene blue in the tissue compression technique to detect sarcocysts in meat-producing animals. *Vet Parasitol* 2015; **214**(1–2): 200-3.
- [51] Poulsen CS, Stensvold CR. Current status of epidemiology and diagnosis of human sarcocystosis. *J Clin Microbiol* 2014; **52**(10): 3524-30.